



# Guidelines for the Sidelines: Common Musculoskeletal Injuries in Sports

**Timothy L. Miller, MD, FAAOS**

*Professor, Department of Orthopaedic Surgery*

*Team Physician*

*Ohio State University Athletics, Team USA, and Granville High School*

*The Ohio State University Wexner Medical Center*

**MedNet21**

Center for Continuing Medical Education



**THE OHIO STATE UNIVERSITY**  
WEXNER MEDICAL CENTER

## History and heritage of team physicians and Sports Medicine doctors



- 2,500 year-old tradition dating to ancient Greece
- Many techniques were developed from battle field care and applied in peacetime to the athlete.
- Herodicus, Galen, and Hippocrates
- 5th century BCE, Herodicus proposed the use of therapeutic exercise for the maintenance of health and the treatment of disease.
- Maintaining balance between strict diet, physical activity, and athletic training was the key to a good standard of health.

Knee Surg Sports Traumatol Arthrosc (2007) 15:315-318  
DOI 10.1007/s00167-006-0149-z

SPORTS MEDICINE


**Herodicus, the father of sports medicine**

Anastasios D. Georgoulis · Irini-Sofia Kiapidou ·  
Lamprini Velogianni · Nicholas Stergiou ·  
Arthur Boland



Whiteside et al. CJSM 2007; Georgoulis et al. KSSTA, 2007.; Snook G, AJSM, 1984.; Appelboom et al, AJSM 1988.

# History and evolution of team physicians and Sports Medicine doctors



Fundamental responsibility of the orthopaedic team physician:  
 “...To develop medical techniques that promote health and fitness while ensuring the safety and well-being of those who participate in athletic competition.”

*Miller et al., CSMR, 2021.*

## Defining a Team Physician

- Duty to provide for the well-being of individual athletes—enabling each to realize his/her full potential.
- Possess special proficiency in the care of musculoskeletal injuries and medical conditions encountered in sports.
- Must actively integrate medical expertise with other healthcare providers and allied health professionals.
- Assumes ultimate responsibility for making medical decisions that affect the athlete's safe participation



### Team Physician Consensus Statement

*Team physician consensus statement. Am J Sports Med. 2000;28(3):440-441.*

## Qualifications of a team physician

### Team Physician Consensus Statement

- Possess a fundamental knowledge of emergency care regarding sporting events
- Be trained in CPR/ BLS and design EAP's
- Carry out medical management of the athlete
- Administrative and Logistical Duties
  - Develop a chain of command
  - Plan and train for emergencies during competition and practice
- [Current Sports Medicine Reports, 2025.](#)
- [NATA.org, 2021.](#)



## Guidelines for the Sidelines

### Common Musculoskeletal Injuries in Sports

- Acromioclavicular Joint Injuries
- Glenohumeral Joint Dislocations
- Patellar Dislocations
- ACL Tears
- High Ankle Sprains





# Sideline Evaluation & Management of the Acutely Dislocated Joint

**Bryant J. Walrod, M.D. C. A. Q. Sports Medicine**

*Professor - Clinical*

*Family and Community Medicine: Sports Medicine*

*Head Team Physician: Football, Ohio State Buckeyes*

*The Ohio State University Wexner Medical Center*

**MedNet21**

Center for Continuing Medical Education



THE OHIO STATE UNIVERSITY  
WEXNER MEDICAL CENTER

## AC Joint Injuries

### ***Static stabilizers***

AC ligaments

- Anteroposterior stability

CC ligaments

- Conoid, Trapezoid

- Superior/ Inferior stability

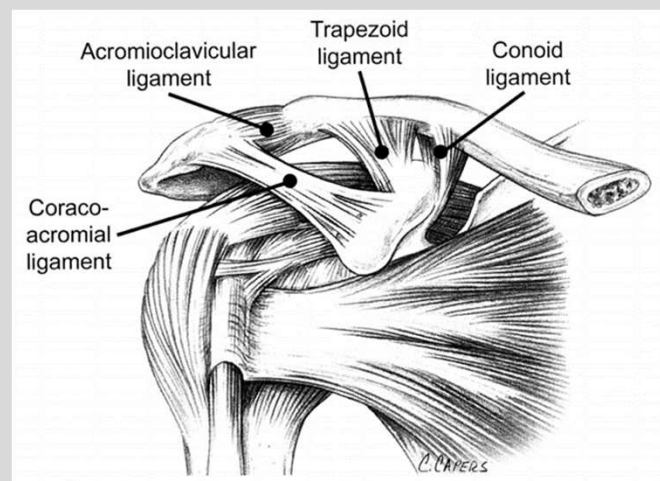
CA ligament

AC joint capsule

### ***Dynamic stabilizers***

- Deltoid, trapezius muscles

- Scapulothoracic articulation





## AC Joint Injuries

### Mechanism of *Injury*

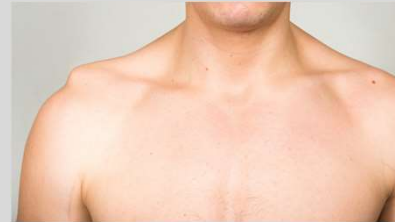#### Direct

- Fall onto lateral aspect of Shoulder
- Inferior displacement of the Scapula
- AC and CC ligament disruption

#### Indirect

- Fall onto elbow
- Proximal humerus driven superiorly into acromion
- Often spares the CC ligaments

Inspection: Visible deformity asymmetry

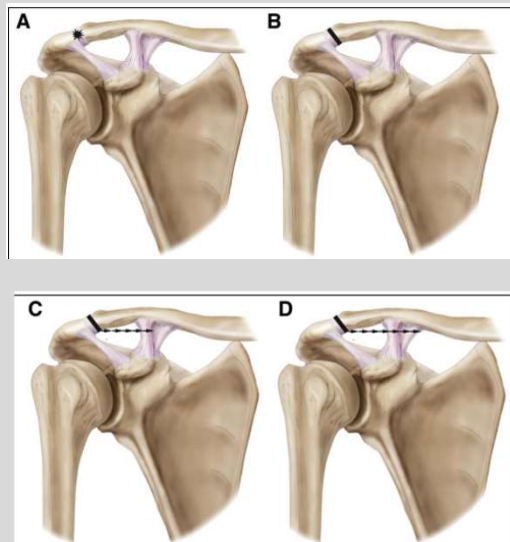


## AC Joint Injuries

### Grading of Severity

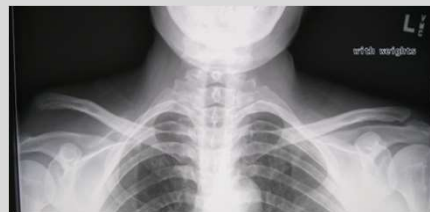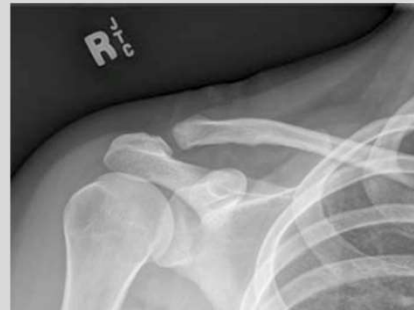- Radiographic Evaluation
- Rockwood Classification
  - Types I-VI
- Sequential Injury
  - AC ligaments
  - CC ligaments
  - Deltotrapezial Fascia

*Kibler et al. JAAOS, 2025.*



## AC Joint Injuries

- Complete Shoulder Series  
AP/Grashey (true AP)  
Scapular Y  
Axillary  
A/P
- Zanca View  
10 deg cephalad tilt, 50% penetration
- Stress View  
Type II vs Type III



## AC Joint Injuries

### Treatment Recommendations

#### Initial Treatment:

- Sling, ice, NSAID's, physical therapy
- Consider Lido/Corticosteroid Injection

#### Definitive Treatment

- Nonoperative

Type I-II (incomplete AC joint disruption)

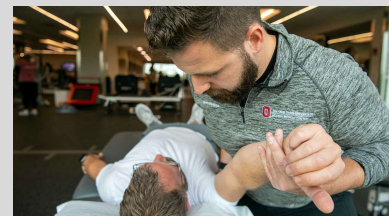
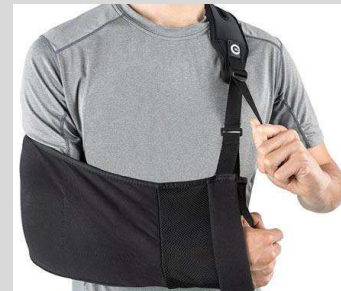Type III controversial

- Surgery for elite throwing athletes.
- Otherwise return to play in 2-6 weeks

- Operative

Type IV-VI (complete AC joint disruption)

([Frank R, et al., JAAOS, 2019.](#))





# Guidelines for the Sidelines: Common Musculoskeletal Injuries in Sports

**Timothy L. Miller, MD, FAAOS**

*Professor, Department of Orthopaedic Surgery*

*Team Physician*

*Ohio State University Athletics, Team USA, and Granville High School*

*The Ohio State University Wexner Medical Center*

**MedNet21**

Center for Continuing Medical Education



**THE OHIO STATE UNIVERSITY**  
WEXNER MEDICAL CENTER

## AC Joint Injuries

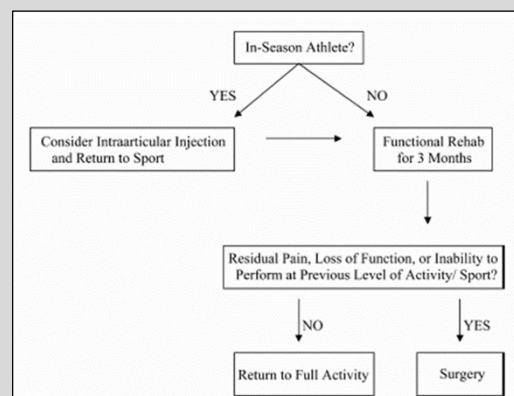
### Type III Treatment Algorithm

Surgery may be indicated for:

- Residual Instability
- Decreased Strength
- AC Joint Pain

Deciding Factors for Type III's

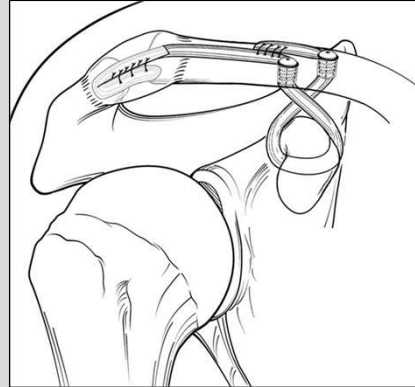
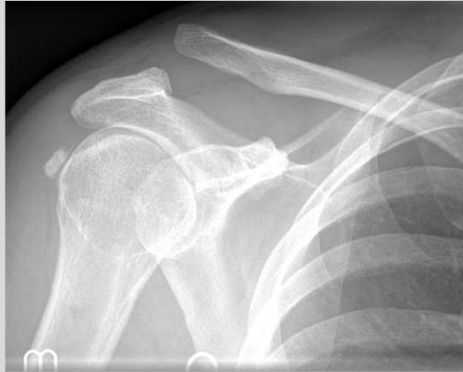- Type of Sport
- Timing of Injury relative to athletic season
- Throwing demands
- Hand dominance



*Beitzel et al. Arthroscopy, 2013.*

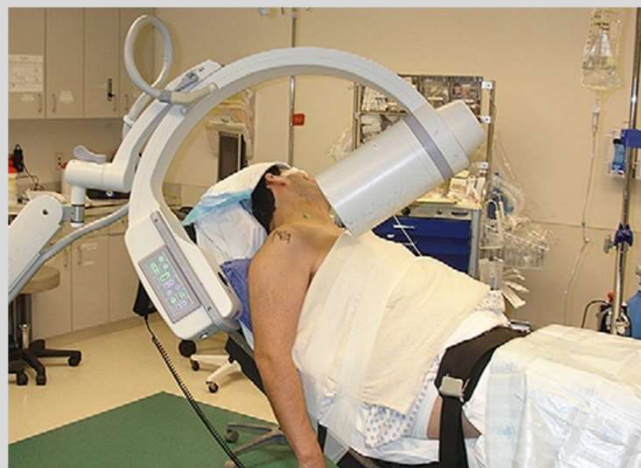*Frank R, et al., JAAOS, 2019.*

## AC Joint Injuries

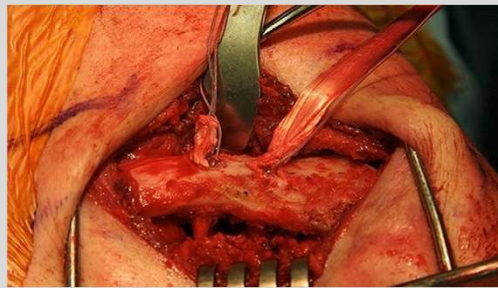
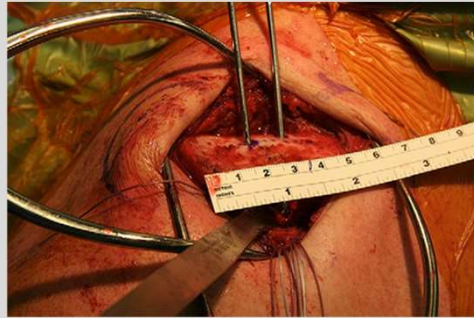
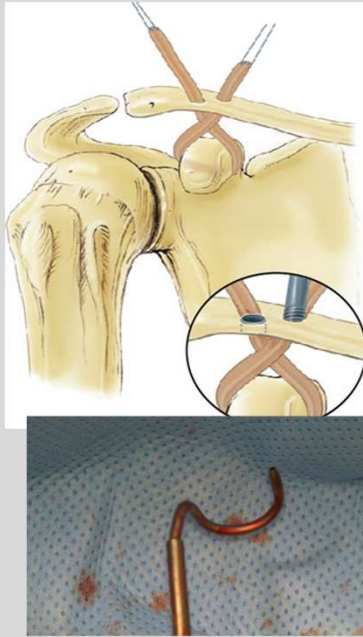


Division II collegiate quarterback with Grade III AC joint dislocation  
Initially treated with PT/ rehab and injections.

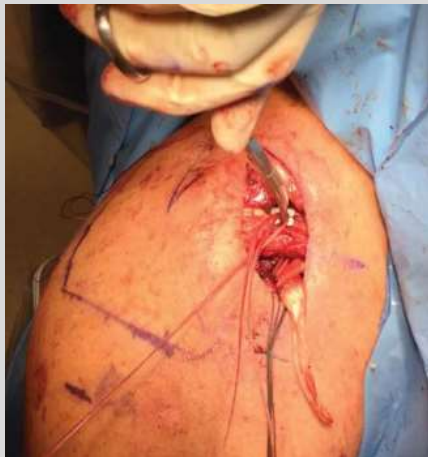## AC Joint Injuries



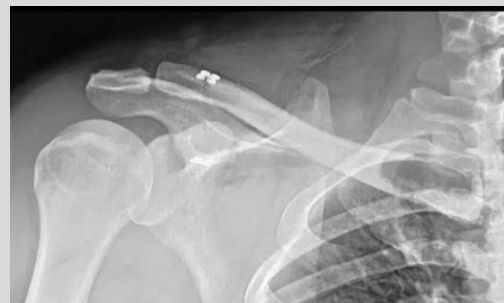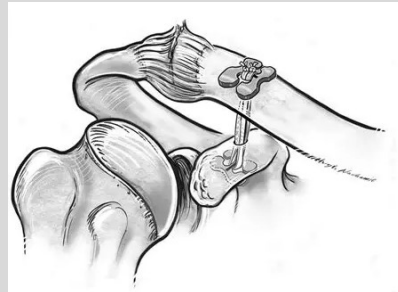
## AC Joint Reconstruction



## AC Joint Reconstruction



Suture button augmentation







## Sideline Evaluation & Management of the Acutely Dislocated Joint

**Bryant J. Walrod, M.D. C. A. Q. Sports Medicine**

*Associate Professor - Clinical*

*Family and Community Medicine: Sports Medicine*

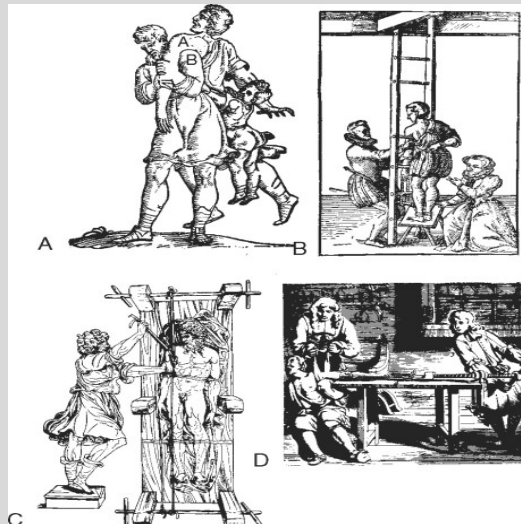
*Head Team Physician: Football, Ohio State Buckeyes*

*The Ohio State University Wexner Medical Center*

**MedNet21**  
Center for Continuing Medical Education

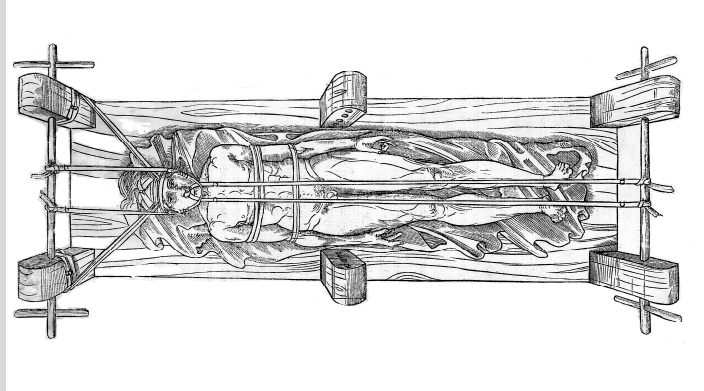
**THE OHIO STATE UNIVERSITY**  
WEXNER MEDICAL CENTER

- "I have never known any physician [to] treat the case properly; some abandon the attempt altogether, and others hold opinions and practice the very reverse of what is proper."
- -Hippocrates  
5<sup>th</sup> Century B.C.

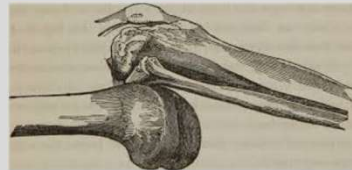

## Joint Dislocation: Goals

- Avoid neurovascular complications
- Reduced the joint with as little trauma as possible
  - “Zen of shoulder reduction”



## Definitions



- **Dislocation**
  - **Complete** displacement of the bone from its normal joint position
  - May or may not need to be reduced
  - May be acute or chronic
- **Subluxation**
  - **Transient** displacement of a bone from its normal joint position
  - Does not need to be reduced
- **Separation**
  - Poor term: Consider acromioclavicular (AC) or sternoclavicular (SC) joint

## Technique & Skill Considerations

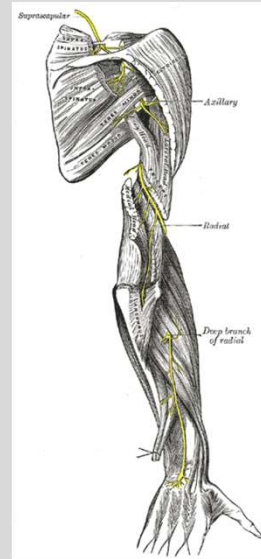
- Patient consent, or parental consent and patient assent in the case of **minors** should be obtained before any attempt at reduction
  - **Consent is often assumed**
  - Written consent **before the start of the school season**
- ATs should collaborate and consult with their supervising physicians
  - Specific criteria to be used in **determining joints for which an onsite reduction will be attempted**
- Physicians should educate ATs on the details of the selected reduction techniques
  - Determine, based upon the skill and experience of the AT, when he or she can attempt specific onsite reduction techniques

## General Joint Dislocation Management Considerations

- History should be obtained
  - **Previous joint dislocations**
  - **Details of current injury**
    - Paresthesia
    - Numbness
    - Neck pain
    - **Concussion symptoms**
      - **Will need to be addressed later**
  - Other medical conditions that may affect injury management
- Comprehensive MSK assessment
  - **Include neurovascular examination**
- Reduction **should not** be undertaken if there are any signs of fracture

## General Management Considerations

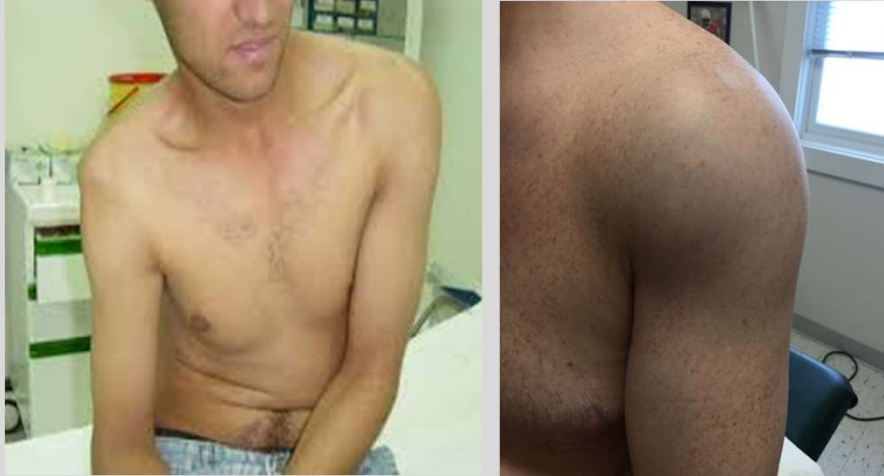- Neurovascular examination
  - Sensory
  - Vascular
  - Motor
- All reduced joints should be immobilized
  - Temporary
  - Buddy tape, sling, knee immobilizer
- Refer for further treatment
  - Radiographs
- **Pediatric patients:**
  - Caution for onsite reduction of a joint dislocation because a **fracture** is highly likely



## Why reduce onsite?

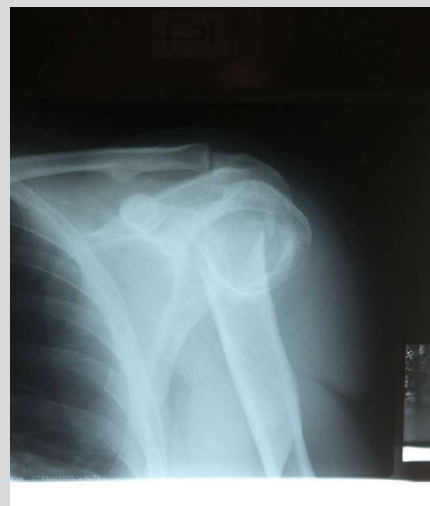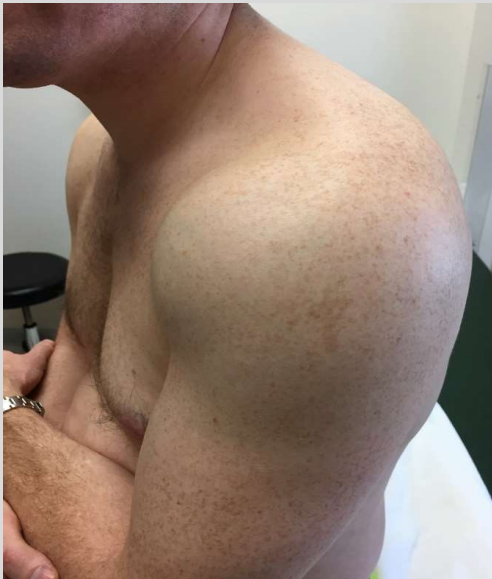- Crucial considerations
  - Protect neurovascular structures
  - Reduce the joint
- Avoid muscle spasm and contraction
- Reduces pain
- Less articular cartilage injury
- Reduce emergent need for radiographs
- Treatment for a dislocation with neurovascular compromise is:
  - **REDUCTION**

## Pearl



Fractures swell – dislocations do not

## Fracture

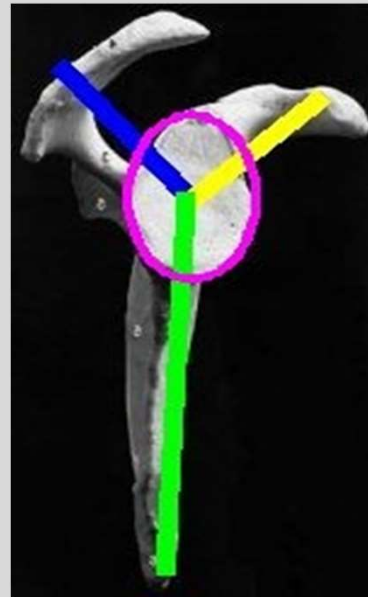




# Shoulder Dislocations

50% of all major joint dislocations

- Anterior: **95-97%**
- Posterior: 2-4%
- Inferior: <1% (luxatio erecta)



## Epidemiology of Shoulder Dislocations Presenting to Emergency Departments in the United States

By Michael A. Zacchilli, MD, and Brett D. Owens, MD

*Investigation performed at William Beaumont Army Medical Center, El Paso, Texas*

Between '02-'06

- .23/1,000 person years
- 72% were in males
- Nearly 50% occur in ages 15-29 years



## Anatomy

Inherently unstable

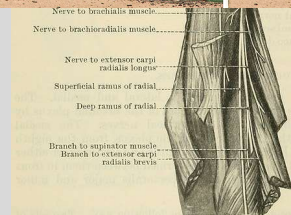
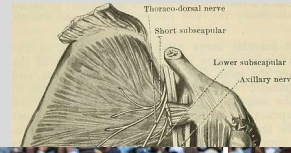


- Labrum
- Articular conformity
- Negative pressure

Dynamic stabilizers

- Rotator cuff

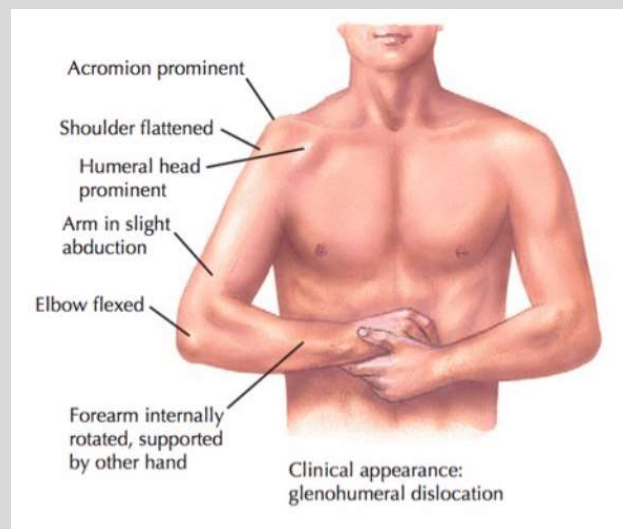
Axillary Nerve



Author: Johnmaxmena2 (CC BY-SA 4.0)

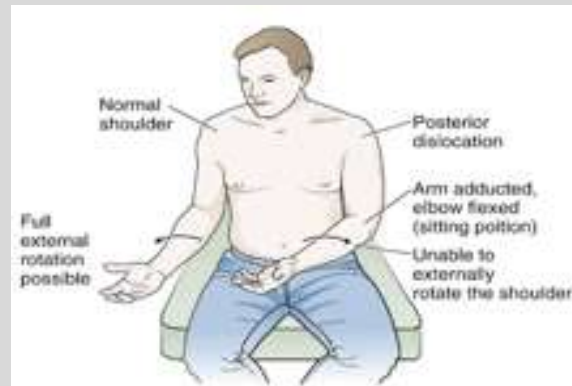## Anterior Dislocation

- MOI: **Abduction & External Rotation**
- Feel the shoulder "Pop out of joint"
- Hold their arm in slight abduction
- Resists movement/guards
- May note a prominent humeral head in thin individuals
- Loss of normal contour of shoulder



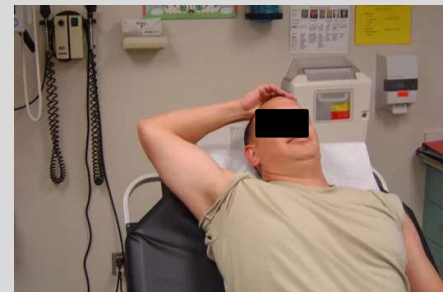## Posterior Dislocation

- Axial loading to the anterior aspect of the shoulder
  - Offensive Lineman
  - Auto accident
- Violent muscle contraction:
  - 3 E's
    - Epilepsy
    - Electrocution
    - EtOH
- Arm is adducted and IR
- Does not want to allow **ER**
- Anterior shoulder is flat with prominent coracoid
- May go unrecognized



## Inferior Dislocation

- MOI
  - Axial load to the arm while fully abducted
  - Forceful hyper-abduction
  - Grab an object above their head while falling
- Hold arm above their head
- Associated **neurologic dysfunction**:
  - Axillary nerve
- Associated **rotator cuff tears and greater tuberosity fractures**
- Highest rate of **vascular compromise** when compared to other directions of instability (3%)



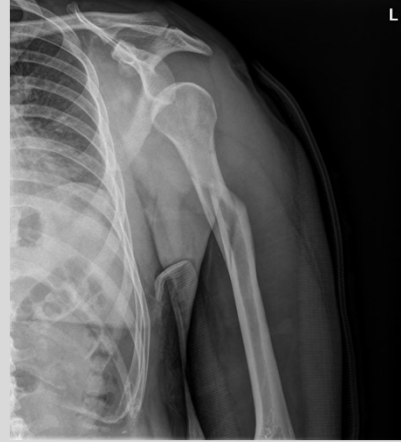## Radiographic Imaging

Ideally obtain radiographs pre/post-reduction

- Confirm diagnosis
- Rule out associated fracture
- Iatrogenic post-reduction fracture

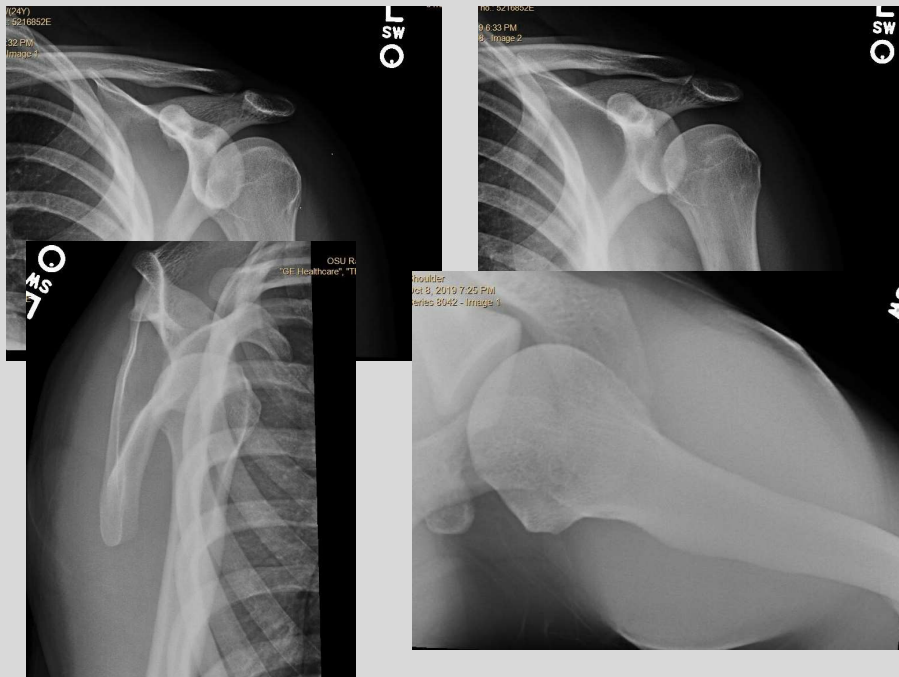
### Fracture

- 25%
- Increased risk:
  - Age >40
  - First time dislocation
  - Trauma



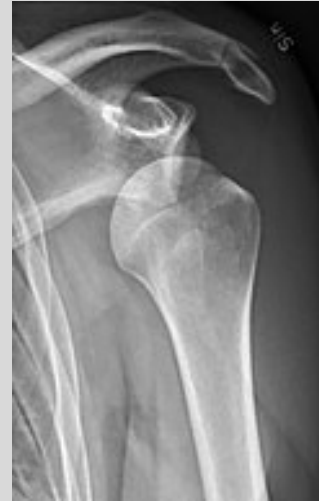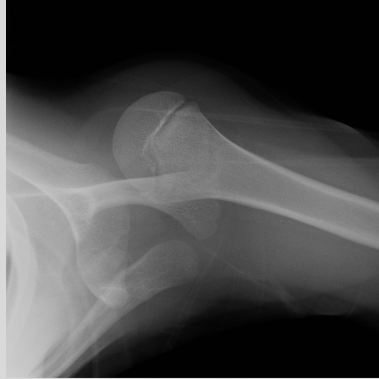**Do not attempt to reduce if there is a fracture**

### Pearl - Need to get all appropriate views

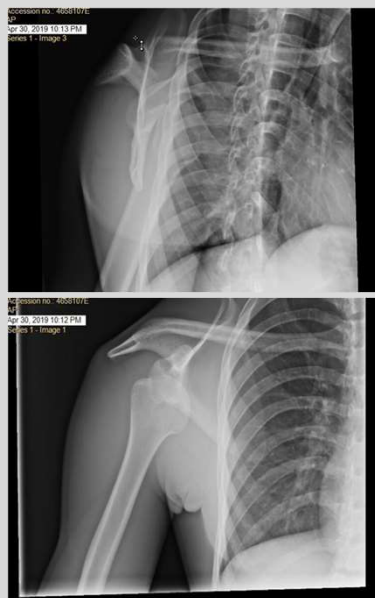

## Anterior Dislocation

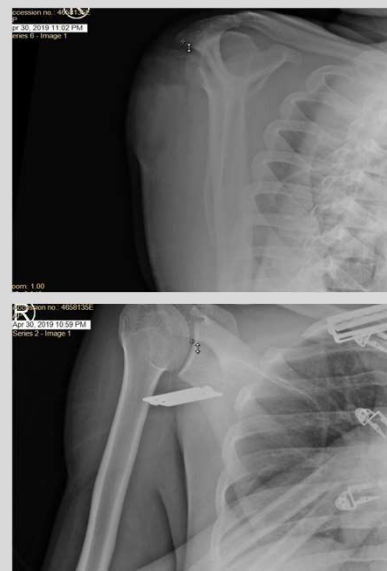
- **Anterior dislocation**
  - **Axillary:** humeral head is anterior
  - **Scapular view:** humeral head is anterior to the center of the Y



### Pre-reduction

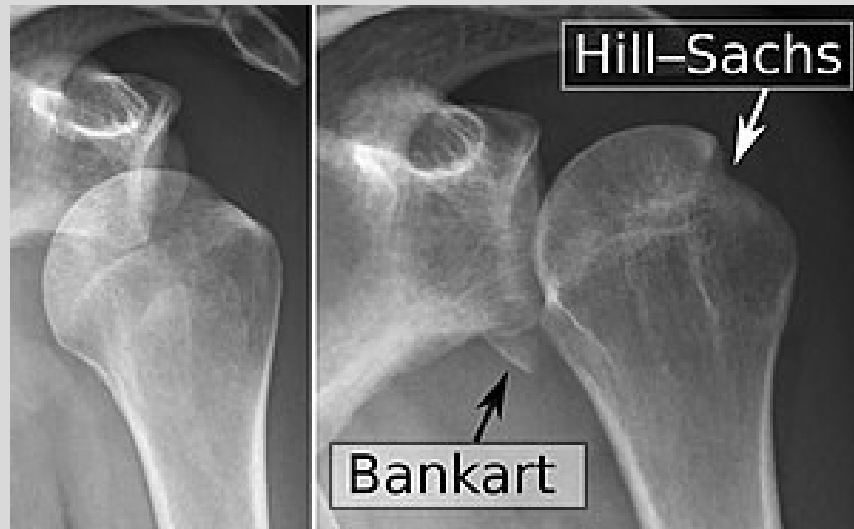


### Post-reduction

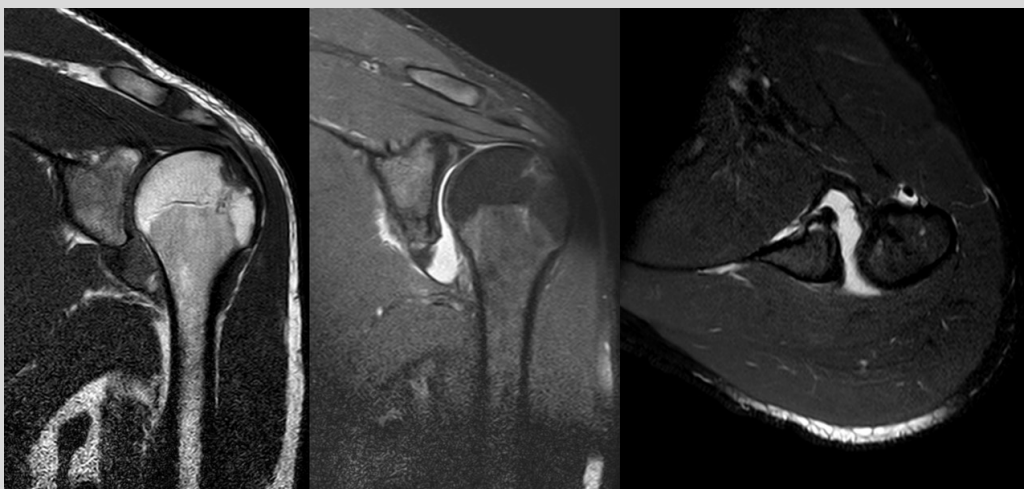




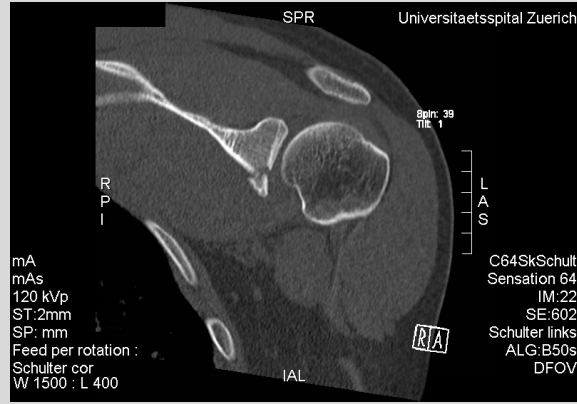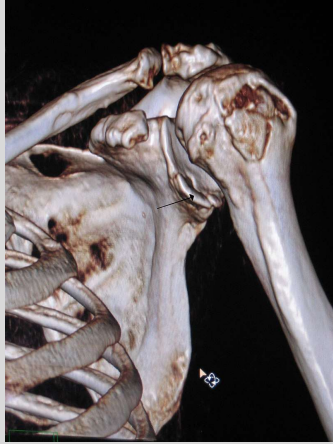## Complications



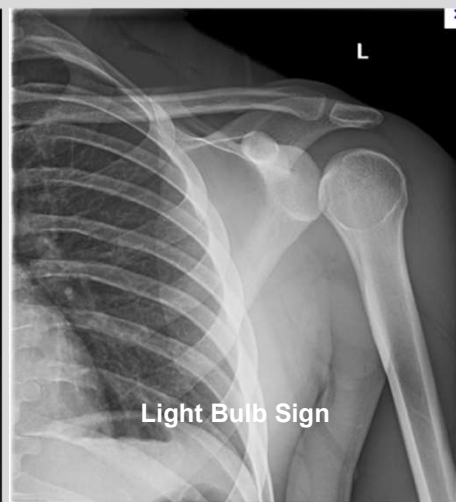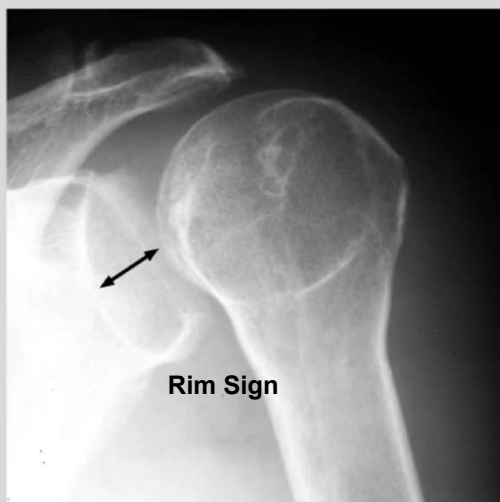## Bankart & Hill-Sachs: MRI



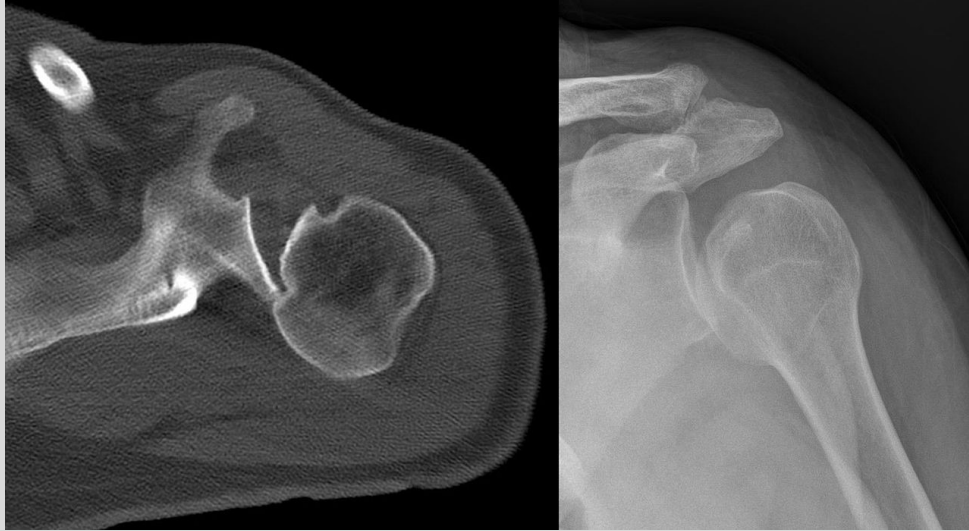## Bankart & Hill-Sachs: CT



## Posterior Dislocation Radiographs



## Reverse Hill-Sachs



## Anesthesia/sedation

- **Consider intra articular lidocaine (5 ml 1%) pre-reduction over procedural sedation**
  - Consider US guidance
  - Equal rates of successful reduction
  - Shorter time to discharge from ED
  - No need for IV
  - Less expensive, less staff needed
  - Less complication
- Procedural anesthesia
  - ED, Ortho
  - Fentanyl, Midazolam, Ketamine, Etomidate, Propofol

## Anterior Reduction Techniques: 21 options

Scapular manipulation

Stimson

External Rotation

Milch

Sitting

Axial traction

Traction/counter traction

Fares

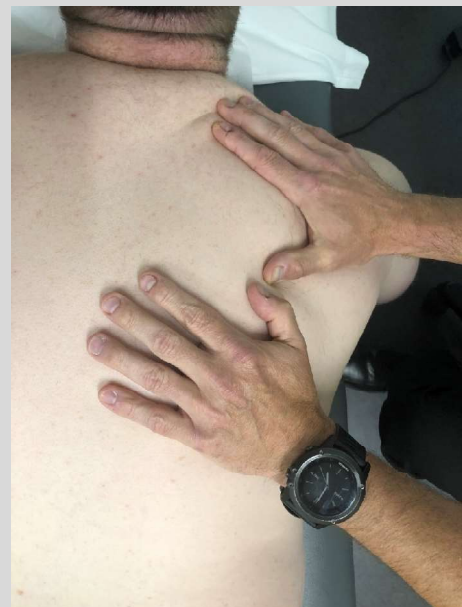
Chair

Elbow



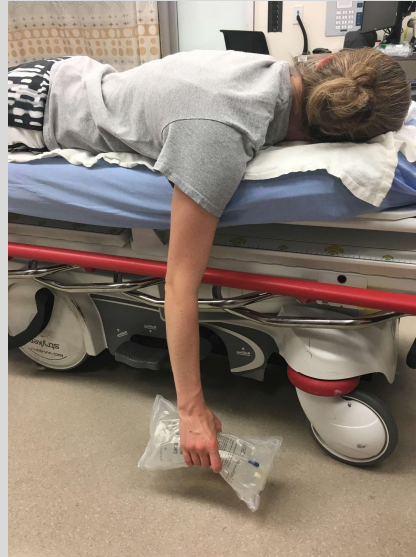## Scapular Manipulation

- Upright or Prone
  - Affected arm is placed at 90° of forward flexion
  - Slight traction is applied
  - From a posterior approach place both hands around the scapular with the thumbs in an inferior lateral position
  - Rotate the inferior tip of the scapula medially and the superior aspect laterally to rotate the scapula
  - Have an assistant continue with gentle downward traction with slight external rotation of the humerus and elbow flexion to 90°
    - May be difficult in obese patients



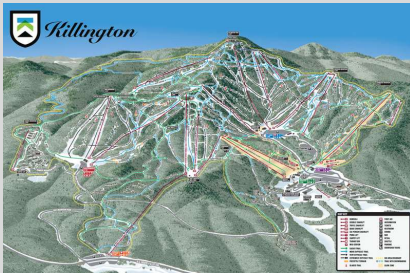# Stimson

- Prone on training table
- Affected arm hangs off the stretcher in 90° of forward flexion
  - Relaxes biceps tendon
- Attach at 10 – 15# weight to the affected hand for counter traction
- Shoulder will usually reduce with in 20 -30 minutes



## My Preferred Technique

Matt Gammons, M.D., James Russell, M.D.



**Jim Russell, MD**, is certified by the American College of Emergency Physicians and holds a certificate in Added Qualifications in Sports Medicine from the same organization.

A long-time Vermonter, Dr. Russell received his B.A. from the University of Vermont and his M.D. from the Medical College of Vermont. He completed his surgical residency at the Medical Center Hospital of Vermont and also in Emergency Medicine at the Institute of Emergency Medicine and Trauma in Milwaukee, Wisconsin. He was also an assistant coach for the U.S. Olympic Sailing Team from 1984 through 1988.

Dr. Russell has been associated with Killington Medical Clinic since 1986 and Vermont Orthopaedic Clinic since 1997.



**Matthew Gammons, MD**, is Medical Director of Killington Medical Clinic, ISPORT Training program of Vermont Orthopaedic Clinic, and Performance Improvement, a department of Rutland Regional Medical Center. He also serves as the Medical Director of Castleton University's Athletic Training Education and Athletic Programs. He is board-certified in family practice and sports medicine. His specialty is in non-operative musculoskeletal care.

He received a BS in Biomedical/Mechanical Engineering from the University of Vermont and then was awarded his MD at Ross University School of Medicine in Portsmouth, Dominica. He served his residency in family practice at Saginaw Cooperative Hospitals in Michigan. He also completed a fellowship in primary care sports medicine at the Medical College of Wisconsin in Milwaukee.

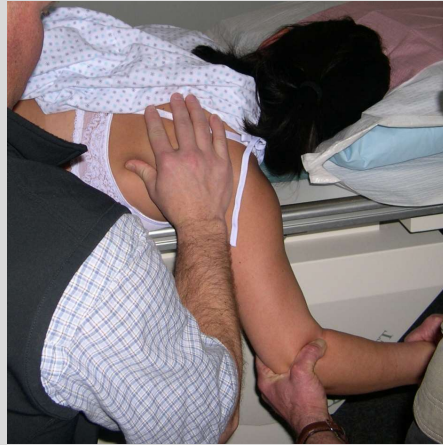Dr. Gammons has been on staff at the Killington Medical Clinic and the VOC since 2004. Previously, he served as the Assistant Residency Director and the Director for Sports Medicine at St. Michael Family Practice Residency in Milwaukee.

In addition to having authored numerous sports medicine-related articles, papers and presentations, Dr. Gammons has been the recipient of several professional honors, including the Harry Galanty Young Investigators Award for Outstanding Research from the American Medical Society for Sports Medicine.

He also enjoys several sports team affiliations, including serving as team physician for the U.S. Ski and Snowboard teams.



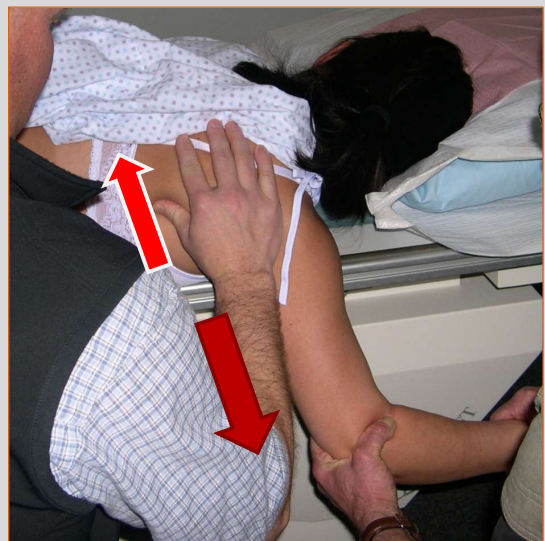**Start with mild humeral traction & then add scapular manipulation**



Pull down to disengage the locking mechanism (window shade)  
Try to avoid letting the humeral head “clunk” in.

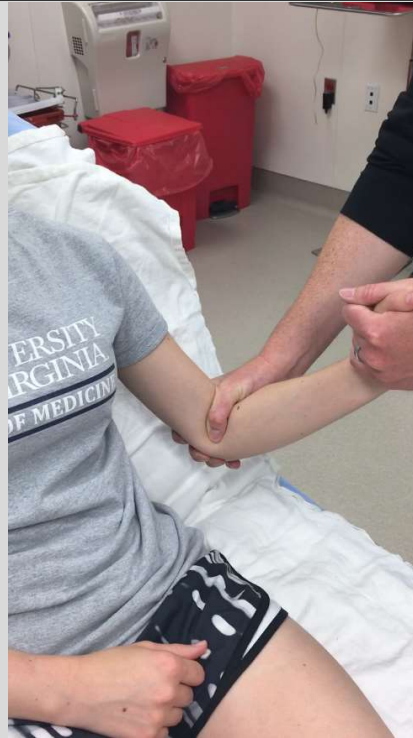**If humeral head is hung upon glenoid the scapula moves with humeral traction and external rotation is blocked**

- Apply increased traction and/or increase medial rotation of the scapula
- Consider forward flexion of the arm



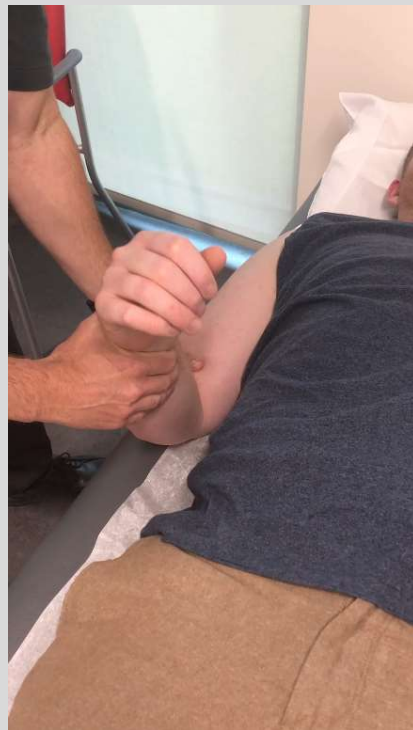## Milch (75-95%)

- Apply gentle longitudinal traction in line with the humerus while maintaining external rotation
- Gentle abduction
- Stop if you feel resistance and then continue when patient relaxes



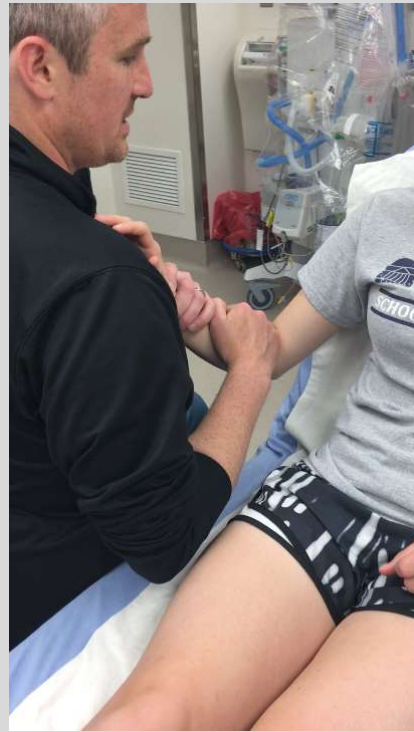
## External Rotation

- Supine on a stretcher
- Adduct affected arm and flex the elbow to 90°
- Consider forward flexing the shoulder to 20°
- Slowly and gently externally rotate the shoulder using the forearm as a lever
- Reduction typically occurs at 70 - 110° of ER
- ***No traction is applied***



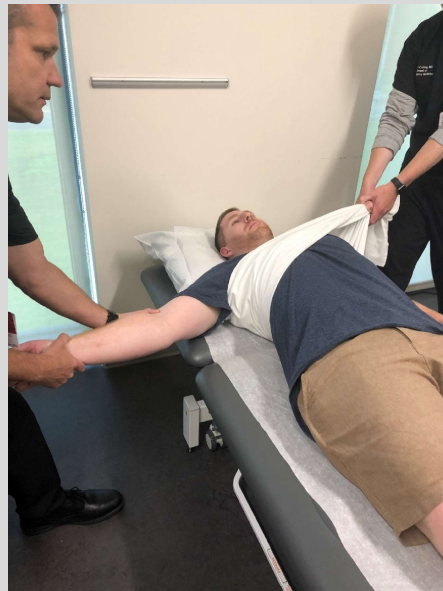## Cunningham (sitting) Method

- Patient is seated facing the practitioner
- Hold the forearm and flex the shoulder to 90° with slight elbow flexion
- Place other arm on anterior chest wall to stabilize the shoulder
- Apply gentle longitudinal traction
- Consider IR or ER to assist with reduction



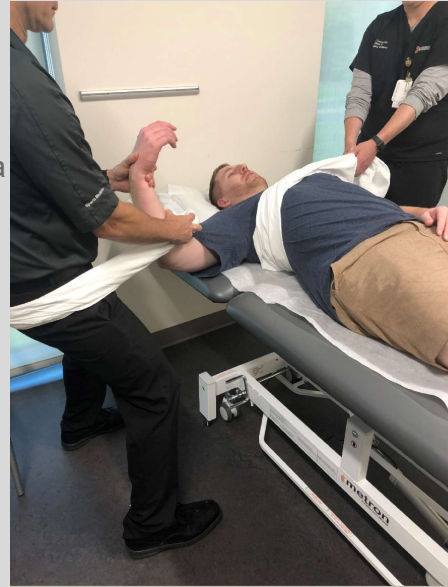## Axial (Inline) Traction

- Supine with wheel locked cart
- Operator on affected side at patient's head
- Apply axial traction in line with the abducted arm
- Assistant can apply parallel counter traction by using a sheet wrapped diagonally around the affected shoulder



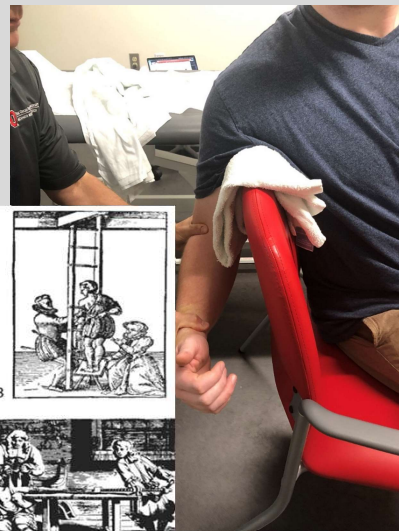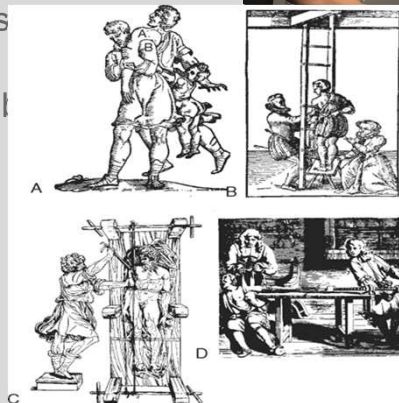
## Traction/Countertraction: Matsen

- Two-person reduction technique
- Supine on a firmly locked stretcher
- Elevate bed to position of operators' ischial tuberosities
- Place a sheet over patient's upper chest, under the axilla of the affected shoulder and underneath the back
- Elbow in 90° of flexion
- Shoulder abducted to 90°
- Apply gentle traction: pull the flexed forearm towards you
  - Lean back pulling along the axis of dislocation
  - **Do not pull with your upper arm muscles**
- **Continuous gentle traction** is superior to forceful yanking



## Chair Technique

- Patients are seated in a chair with a backrest as the fulcrum in the axilla
- A folded towel is placed in the axilla for padding and to minimize risk to the axillary nerve
- Hang dislocated arm over the back of the chair
- Elbow is flexed to 90°
- Provide gentle inferior traction

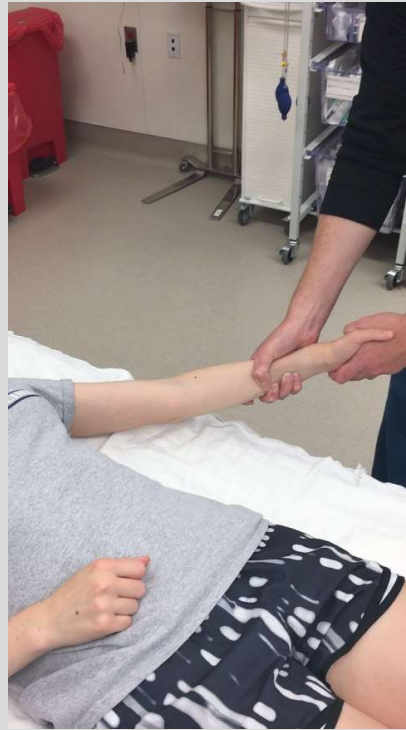

2012: Mahirogullari



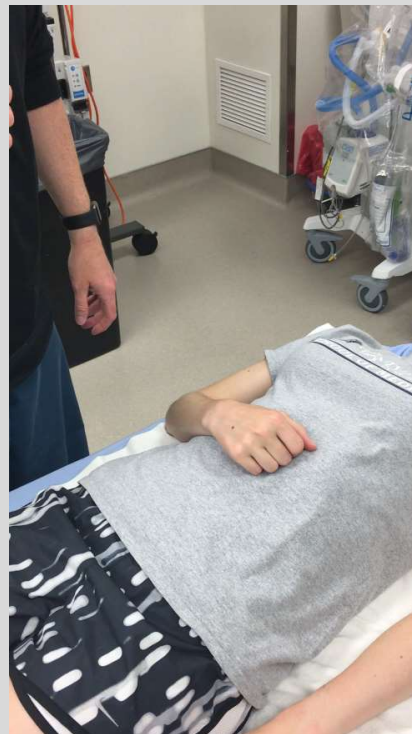## Fares (FASt RELiable Safe)

- Patient supine
- Grasp the wrist of the patient
- Maintain the elbow in extension and the forearm in neutral
- Slowly abduct the arm in an oscillating movement
  - 5cm up and down
- Continuous application of longitudinal traction
- When arm is abducted past 90°, then begin ER
- Reduction typically occurs at 120°



## Elbow Technique

- Supine position
- Hold patient's wrist with outer hand and apply gentle traction to keep the elbow straight
- Affected arm is then lifted to 45° of forward flexion and abduction
- Operator pushes the lateral surface of their elbow into the medial aspect of the patient's humerus



Lo et al, 2/2019. J. of Emergency Medicine

## Older techniques: not recommended

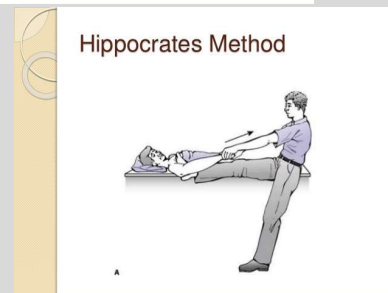
### Kocher

- Adduct arm with elbow bent to 90°, ER to 70-85° until resistance is felt and then lift arm in sagittal plane and internally rotate
- High incidence of complications
  - Axillary nerve injury
  - Humeral neck and shaft fractures
  - Capsular damage



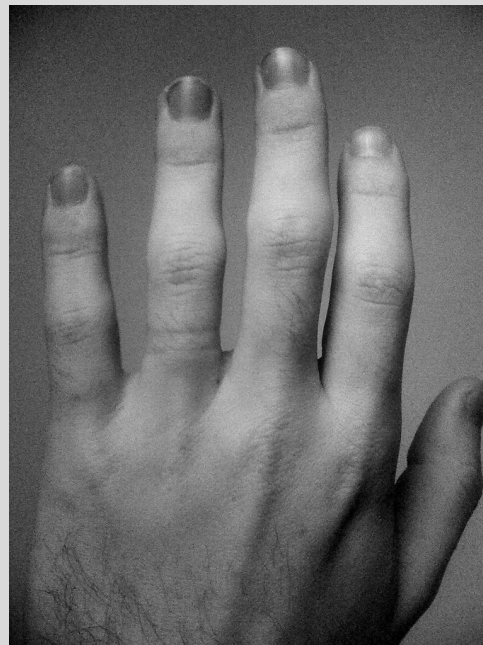
### Hippocratic

- High incidence of complications
- Place foot in padded axilla and apply counter traction



## Pearl

- Remove jewelry distal to the dislocation
- Fingers can swell after elbow and shoulder dislocations







# Guidelines for the Sidelines: Common Musculoskeletal Injuries in Sports

**Timothy L. Miller, MD, FAAOS**

*Professor, Department of Orthopaedic Surgery*

*Team Physician*

*Ohio State University Athletics, Team USA, and Granville High School*

*The Ohio State University Wexner Medical Center*

**MedNet21**

Center for Continuing Medical Education

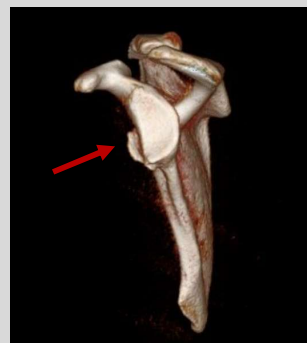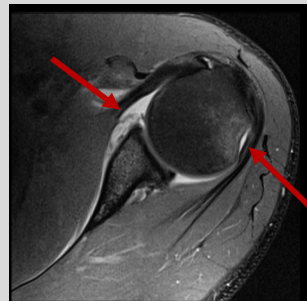


THE OHIO STATE UNIVERSITY  
WEXNER MEDICAL CENTER

## Glenohumeral Joint Dislocations

### Advanced Imaging

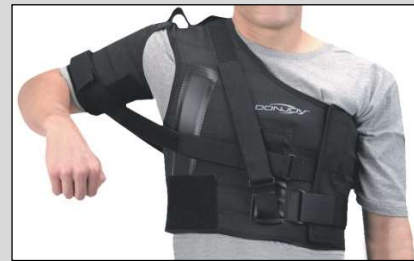- MRI
  - Labral tears
  - Cartilage injury
  - Loose fragments
  - Rotator cuff injuries
- CT Scan
  - Glenoid bone loss
  - Hill-Sachs lesions



*Streubel P et al., JAAOS, 2014..*

## Glenohumeral Joint Dislocations

- Return to Play
  - Sport
  - Position
  - Bracing
  - Risk Factors
- Surgery vs Rehab
- Timing of Surgery
- Type of Procedure



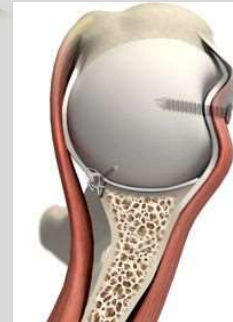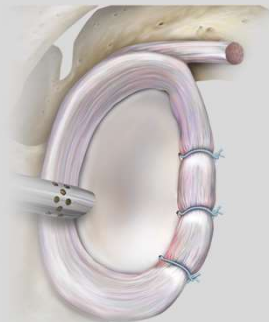*Owens et al., JAAOS, 2012.*  
*Dickens et al., AJSM, 2014.*

## Glenohumeral Joint Dislocations

### Surgical Options

#### Soft Tissue:

- Bankart Repair/  
Capsulorrhaphy
  - Arthroscopic
  - Open
  - Remplissage

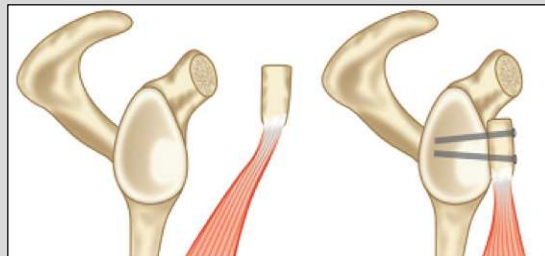


#### Bone:

- Latarjet Procedure

*Owens et al. OJSM, 2015.*

*Provencher et al., JAAOS, 2021.*



## Shoulder Injuries in Athletes

- Shoulder injuries are extremely common in contact sports. (Football, wrestling, hockey, and lacrosse)
- AC sprains can be very painful but rarely require surgery.
- Type III AC injuries may require surgery in a throwing athlete's dominant shoulder.
- Closed reduction of a glenohumeral dislocation can be performed prior to obtaining radiographs.
- Always get post-reduction radiographs including an axillary view or equivalent. (Velpeau view or CT scan)
- Athletes can return to play in the same season following glenohumeral dislocation or AC joint sprain.



## Guidelines for the Sidelines: Common Musculoskeletal Injuries in Sports

**Timothy L. Miller, MD, FAAOS**

*Professor, Department of Orthopaedic Surgery*

*Team Physician*

*Ohio State University Athletics, Team USA, and Granville High School*

*The Ohio State University Wexner Medical Center*

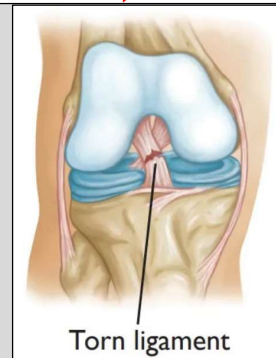
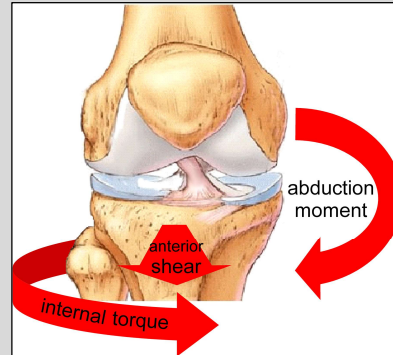
## ACL Tears

### Ligament Function

The primary function:  
Prevent anterior translation of  
the tibia relative to the femur

Secondary functions include:

- Prevention of knee hyperextension
- Resisting varus/valgus angulation
  - Particularly if the collaterals are injured
- Resisting internal tibial rotation relative to the femur near extension



## ACL Tears

### Injury Mechanism

- Females are more commonly affected  
(2-8 x risk of males)
- Cutting and pivoting sports are highest risk
- Non-Contact Injuries:  
75% of ACL injuries
- Deceleration move:  
Change of direction  
Stop, cut, or landing  
Many factors contribute



## ACL Tears

### *Injury Mechanism*

#### Contact Injuries:

- 25% of ACL injuries
- Result from a direct blow to the knee or leg sometimes with rotation
- Concurrent injuries frequent (fractures, multiple ligaments, meniscus, and cartilage)



## ACL Tears

### *Physical Examination*

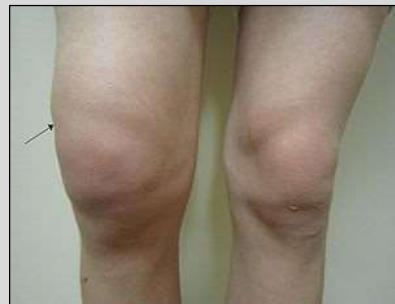#### History:

- Feeling and/ or hearing a “Pop”
- Unable to continue playing or bear weight
- Immediate swelling



#### Lower extremity examination:

- Strength, ROM, neurovascular, gait
- Beware of patella dislocation, can have similar clinical presentation



#### Ligamentous Exam

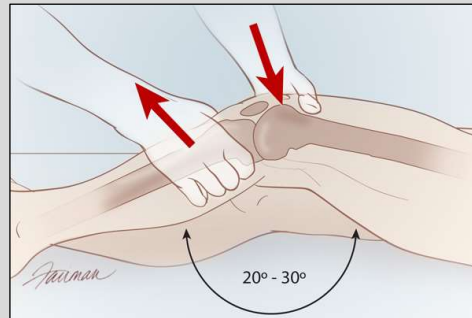
- ACL-Specific tests
- PCL, MCL, LCL, PLC

*Special tests*

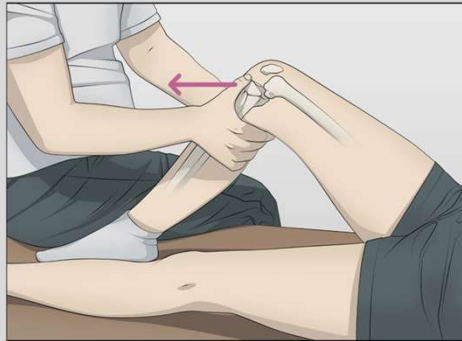
## ACL Tears

Lachman test

- Knee flexed 20-30°
- Stabilize femur, pull anteriorly on proximal tibia
- Evaluate Anterior Excursion / Endpoint
- Most sensitive exam for ACL tear

Anterior drawer test:

- Knee flexed 90 degrees
- Pull forward on the proximal tibia
- Not as sensitive as Lachman



Always perform bilaterally!!

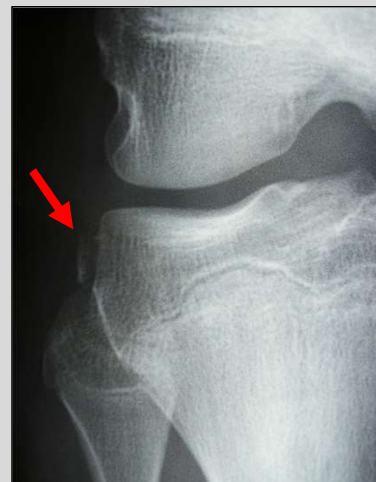## ACL Tears

### Radiographs

Critical to rule out other injuries  
(fractures/ dislocations)

### Segond Fracture

- Pathognomonic for ACL tear



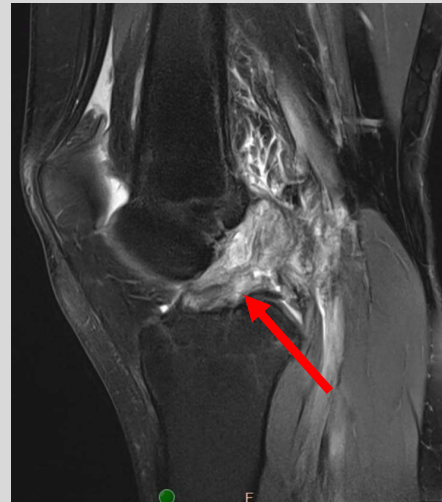

## ACL Tears

### *Imaging Evaluation*

#### MRI Scan:

- Most sensitive and specific test for evaluation of the ACL
- High T2 signal in intra-articular notch
- Discontinuity and inability to visualize remaining fibers



## ACL Tears

### *Associated Injuries*

#### Bone bruises

Lateral femoral condyle terminal sulcus

Posterior lateral tibial plateau

#### Meniscus tear

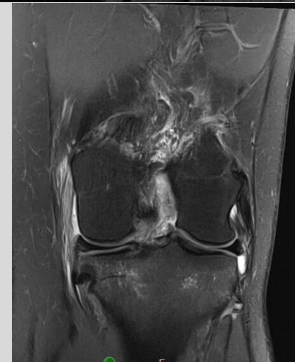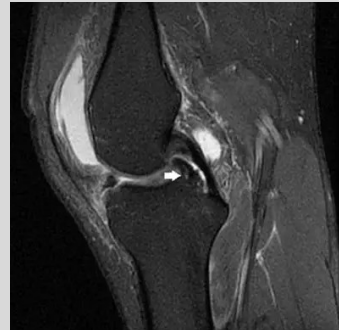40% of index ACL injuries

Lateral meniscus more common in acute injuries

Medial meniscus in chronic injuries

#### MCL

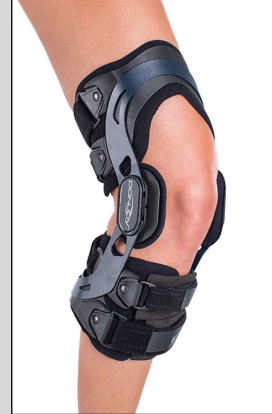Common, usually grade 1 or 2



## ACL Tears

### Non-Surgical Treatment:

- Includes PT and bracing
- Good option in some patients not wanting to return to cutting/ pivoting sports
- Some “copers” may do well without an ACL in all activities
- Prolonged ACL deficiency is associated with increased risk of meniscus tear and osteoarthritis.



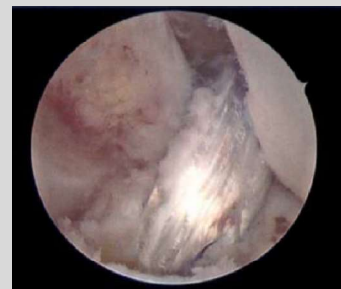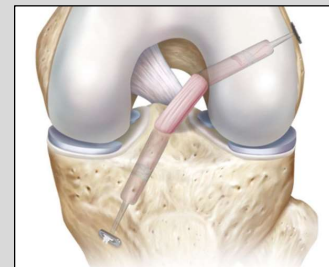
Eastlack et al, MSSE, 1999  
Oiestad et al, AJSM, 2009  
Neyret et al, RCO, 1988

## ACL Tears

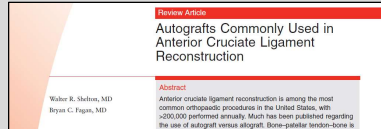
### *Treatment Options*

#### Surgical Treatment:

- Recommended in the majority of athletes wishing to return to cutting/ pivoting sports
- Timing
  - Usually 2-3 weeks post-injury
  - Pre-hab PT important to regain quadriceps strength.
- Graft choice
  - Patellar tendon
  - Hamstrings
  - Quadriceps tendon
  - Allograft
- Augmentation
  - Suture Tape
  - Lateral soft tissue tenodesis
  - Tibial slope correction.



## Comparing Autografts... Which one is the best?



- Highly debated
- No clear favorite
- Surgeon preference/ experience reigns

*Shelton et al., JAAOS, 2011.*

**Factors to Consider in Anterior Cruciate Ligament Autograft Selection**

Graft Type	Anterior Knee Pain	Anterior Knee Numbness	Failure Rate	Knee Tightness	Residual Weakness	Extension	Patient Satisfaction
BPTB	High	High	Low	High	Quadriceps muscle	High	High
Hamstring	Low	Low	Slightly higher	Slightly lower	Hamstrings	Low	High
Quadriceps	Low	Low	Low	High	Quadriceps muscle	Low	High

BPTB = bone–patellar tendon–bone

*J Am Acad Orthop Surg 2011;19: 259-264*

## Suture Tape Augmentation

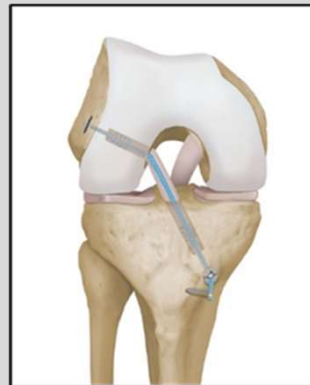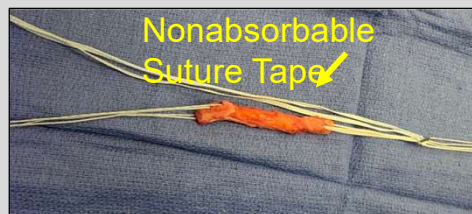### Patellar Tendon Graft Anterior Cruciate Ligament Reconstruction Technique With Suture Tape Augmentation

Roddy McGee, D.O., Matthew Daggett, D.O., M.B.A., Ashley Jacks, B.S., Victor Hoang, D.O., and Heather Ann Theobald, D.O.

- Applicable to all graft types.
- Applicable to all-inside fixation techniques.
- Improves maintenance of suture button against femoral surface during graft passage.
- Canine models indicate biocompatibility of polyethylene suture tape with minimal synovitis
- Re-tear rate decreased to 1% over 5 years.

*Smith et al., J Knee Surgery, 2019.*

*Smith et al., AJSM 2023.*



## Expert Consensus on return to sport after ACL Surgery

Clearance to full participation (practice followed by competition) should be a multidisciplinary decision involving the patient, parent if the patient is under 18 years of age, surgeon, team physician, and physical therapist/athletic trainer (agree 26/26; 100%)

The decision to release an athlete to RTS should consider contextual factors (type of sport, time of season, position, level of competition, etc) (agree 26/26; 100%)

Purely time-based RTS decision-making should be abandoned in clinical practice (agree 26/26; 100%)

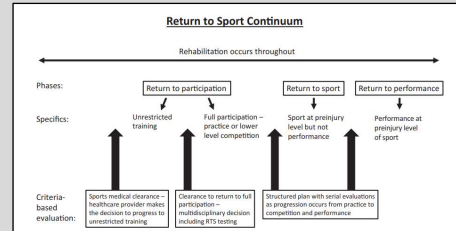
intensity and performance demands.

Consensus Statement

### Return to Sport After Anterior Cruciate Ligament Injury

#### Panther Symposium ACL Injury Return to Sport Consensus Group

Sean J. Meredith, MD, Thomas Rauer, MD, Terese L. Chmielewski, PT, PhD, SCS, Christian Fink, MD, Theresa Diermeier, MD, Benjamin B. Rothrauff, MD, PhD, Eleanor Svanfesson, MD, Eric Hamrin Senorski, PT, PhD, MSc, Timothy E. Hewett, PhD, FACS, Seth L. Sherman, MD, Bryson P. Lesniak, MD, and the Panther Symposium ACL Injury Return to Sport Consensus Group



## ACL Tears

### Return to Play Decision Making

- No return to play same day!
- Vast majority require surgical reconstruction to regain stability for cutting sports.
- Knee must be fully rehabilitated with physical therapy.
  - Full ROM
  - Near full quadriceps strength (80%)
- Time to return to sports after surgery:
  - 6-12 months.
- Running gait analysis?



Miller et al., AJSM 2019.

## Criteria for return to sports after ACL surgery...

- >/ = to 9 months post-reconstruction  
(Minimum 6 months post-reconstruction)
- Must complete PT program based on current institution ACL recovery protocol.
- Full active and passive ROM (within 3 degrees of uninjured knee)
- Isokinetic testing showing quadriceps and hamstring strength and contractility to be within 10% of uninjured side.
- May do in-line running for Track and Field at 6 months if all other criteria are met.

ACL CLINICAL PRACTICE GUIDELINE	
Program is time and criterion based, dependent on self-focus testing, patient demographics, and clinician evaluation. Contact Ohio State Sports Medicine Physical Therapy at 614.293.2385 if questions arise.	
Summary of Recommendations	
Precautions:	<ol style="list-style-type: none"> <li>No loading of repeated or uncontrolled ligaments (Anterior/Posterior Drawer, Varus/Valgus Stress) prior to 12 WEEKS.</li> <li>No resisted, resisted hamstring exercises for 8 weeks with hamstring contract.</li> <li>No loaded knee flexion (less than knee extension) greater than 90 degrees for 12 WEEKS.</li> <li>Hamstring Isometrics:             <ol style="list-style-type: none"> <li>No weight bearing (90°) isometric exercise 180° x 8 WEEKS.</li> <li>Only as tolerated.</li> <li>No closed kinetic segment 90° at 12 WEEKS.</li> </ol> </li> </ol>
Outcomes:	<ol style="list-style-type: none"> <li>Control at least one of the following at initial evaluation, monthly and discharge. See comments and notes on each.</li> <li>ROM:             <ol style="list-style-type: none"> <li>ACL ROM</li> <li>ACL ROM</li> <li>ACL ROM</li> </ol> </li> <li>Strength:             <ol style="list-style-type: none"> <li>Isometric testing of patella. Head in 90°.</li> <li>Isometric testing in either 12° or 90°.</li> </ol> </li> </ol>
Criteria for Discharge:	<ol style="list-style-type: none"> <li>Full active knee extension: full pain on passive extension.</li> <li>Full active knee flexion: full pain on passive flexion.</li> <li>Full active knee extension: full pain on passive extension.</li> <li>Full active knee flexion: full pain on passive flexion.</li> <li>Full active knee flexion: full pain on passive flexion.</li> <li>Full active knee flexion: full pain on passive flexion.</li> <li>Full active knee flexion: full pain on passive flexion.</li> <li>Full active knee flexion: full pain on passive flexion.</li> <li>Full active knee flexion: full pain on passive flexion.</li> <li>Full active knee flexion: full pain on passive flexion.</li> </ol>
Criteria for Return to Sport:	<ol style="list-style-type: none"> <li>Full active knee extension: full pain on passive extension.</li> <li>Full active knee flexion: full pain on passive flexion.</li> <li>Full active knee extension: full pain on passive extension.</li> <li>Full active knee flexion: full pain on passive flexion.</li> <li>Full active knee flexion: full pain on passive flexion.</li> <li>Full active knee flexion: full pain on passive flexion.</li> <li>Full active knee flexion: full pain on passive flexion.</li> <li>Full active knee flexion: full pain on passive flexion.</li> <li>Full active knee flexion: full pain on passive flexion.</li> <li>Full active knee flexion: full pain on passive flexion.</li> </ol>

Criteria for Return to Sport	
1. ROM: full, painfree knee ROM, symmetrical with the uninjured limb	
2. Strength: Isokinetic testing 90% or greater for hamstring and quad at 60°/sec and 30°/sec	
3. Effusion: No reactive effusion ≥ 1+ with sport-specific activity	
4. Weight Bearing: normalized gait and jogging mechanics	
5. Neuromuscular control: appropriate mechanics and force attenuation strategies with high level agility, plyometrics, and high impact movements	
6. Functional Hop Testing: LSI 90% or greater for all tests	
7. Physician Clearance	

## ACL Tears

### Braces

- No data that braces are effective in prevention of ACL tears

- May prevent MCL injuries

### Neuromuscular training programs

- Can reduce at risk positions
- Have been shown to reduce ACL injury risk in females to that of males

Griffin et al, JAAOS, 2000

Hewett et al, J Knee Surg, 2005

Magnussen et al, AJSM 2018

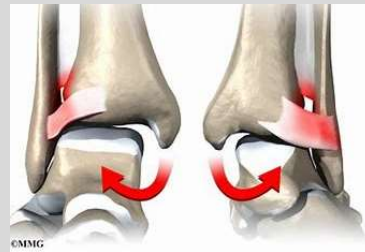## ACL Injuries in Sports

### Take Home Points

- ACL tears by non-contact are common in sports.
- ACL tear leads to immediate effusion; Patellar dislocation swelling may take several hours to develop.
- Presents with history of a feeling a pop, swelling, and instability.
- Radiographic evaluation is crucial to rule out fracture or dislocation.
- ACL tears are most commonly non-contact injuries.
- ACL tears in athletic patients nearly always require surgical reconstruction.
- Many graft options exist. None are perfect.

## High Ankle Sprains/ Syndesmotic Disruption

- Occur from external rotation and eversion mechanisms.
- Less common than inversion sprains but take longer to recover.
- Common in contact sports and athletes wearing rigid footwear (hockey skate, ski boot)
- Multidirectional instability with sagittal instability more critical than once thought. More than coronal instability.

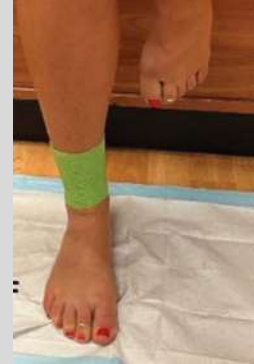
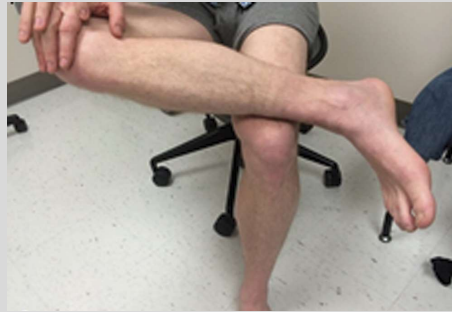
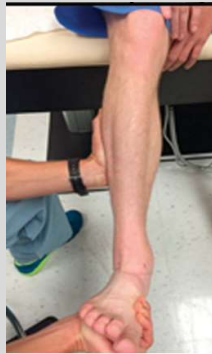*Bejarano-Pineda, et al. Diagnosis and Treatment of Syndesmotic Unstable Injuries. JAAOS, 29(23):p 985-997, 2021.*

*Wake, et al., Syndesmosis Injury From Diagnosis to Repair: Physical Examination, Diagnosis, and Arthroscopic-assisted Reduction. JAAOS, 28(13):p 517-527, 2020.*



## Syndesmosis Disruption- Physical Examination



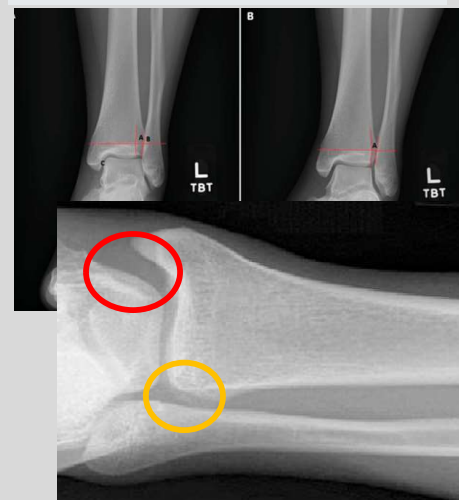
- Physical exam should include:
  - External rotation stress test
  - Cross-leg stress test
  - Single leg hop/ Tape test
  - Shuck test

*Wake et al. JAAOS 2020.*

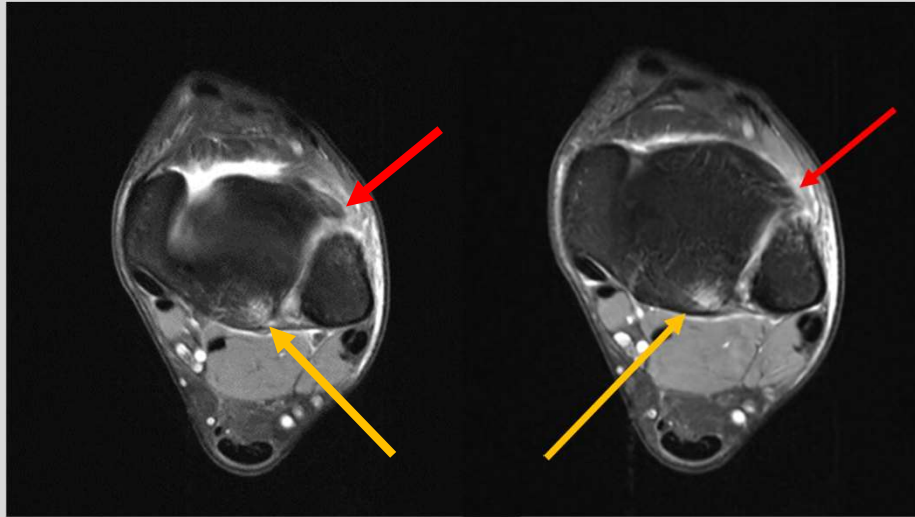
## Syndesmosis Disruption- Imaging Evaluation

- Using the contralateral extremity is most reliable for determining normal relationship of the distal tibiofibular joint.
- Radiographic parameters → Gravity stress X-Ray
- Posterior malleolar edema or ligamentous disruption on MRI

Normal Radiographic Parameters		
Factors	AP	Mortise
Tibiofibular overlap	>6 mm	>1 mm
Medial clear space		Less than or equal to 4 mm
Tibiofibular clear space	<6 mm	<6 mm



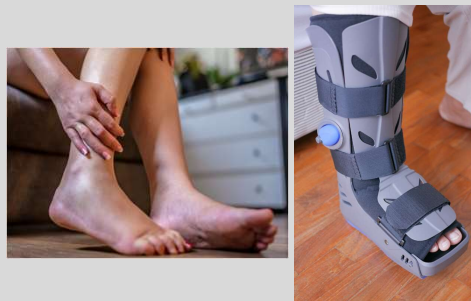## Syndesmosis Disruption: MRI findings



20 year-old female Division I collegiate and Olympic ice hockey player showing avulsion of AITFL from the fibula

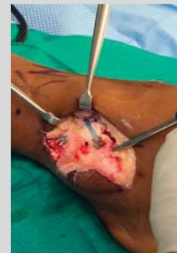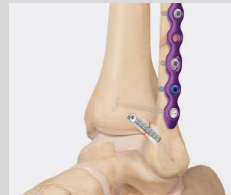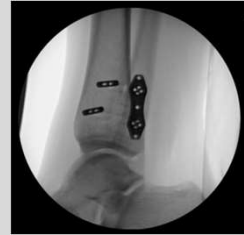
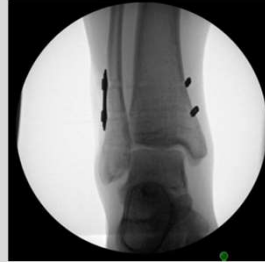## Syndesmosis disruption- Non-surgical treatment

- Early mobilization in syndesmosis injuries may place unwanted stress at the distal tibiofibular joint.
- Protected weight-bearing in a CAM boot from days 4-7.
- Functional rehabilitation begins at 1 week or when pain allows open-chain exercises.
- Recovery time for low syndesmosis injuries can exceed a month.
- In an observational study of NFL players → average time loss of 2.5 weeks, 11.7 practices, and 1.4 games from syndesmotic injury compared with 1.25 weeks, 3.5 practices, and 0.3 games from lateral ankle sprains.
- [Wake, et al., JAAOS, 2020.](#)



## Syndesmosis disruption- Surgical stabilization

- Fluoroscopic and arthroscopic evaluation of stability
- Anatomic reduction improves functional outcome and decreases risk of osteoarthritis.
- Dynamic/ suture button fixation offers more physiologic state and higher rate of anatomic alignment.
- AITFL reconstruction with suture tape augmentation may improve sagittal stability.



## High Ankle Sprains/ Syndesmotic Disruption

- Occur by eversion and external rotation mechanism
- Less common than inversion lateral ankle sprains
- Take longer to recover and return to sports than inversion sprains.
- Obtain stress radiographs to determine stability.
- High grade injuries may require surgical stabilization to allow return to sports.





# Sideline Evaluation & Management of the Acutely Dislocated Joint

**Bryant J. Walrod, M.D. C. A. Q. Sports Medicine**

*Associate Professor - Clinical*

*Family and Community Medicine: Sports Medicine*

*Head Team Physician: Football, Ohio State Buckeyes*

*The Ohio State University Wexner Medical Center*

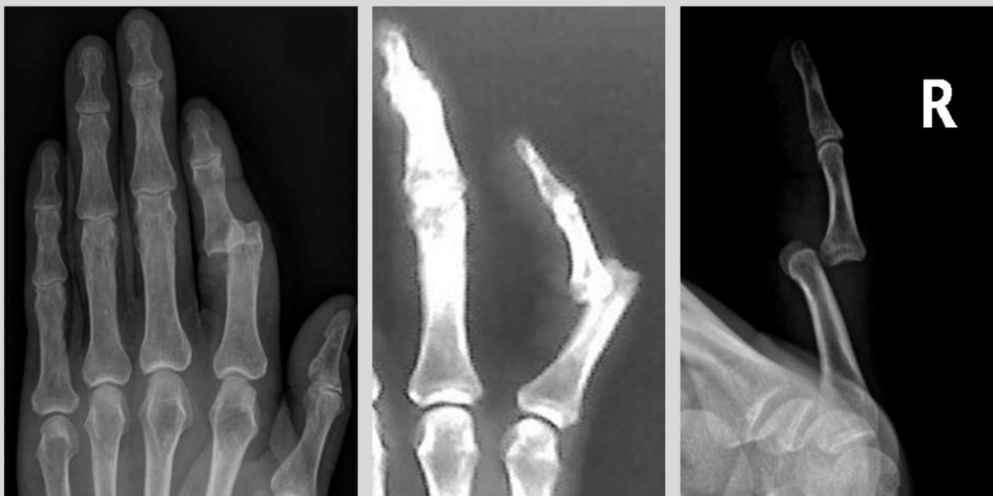**MedNet21**

Center for Continuing Medical Education

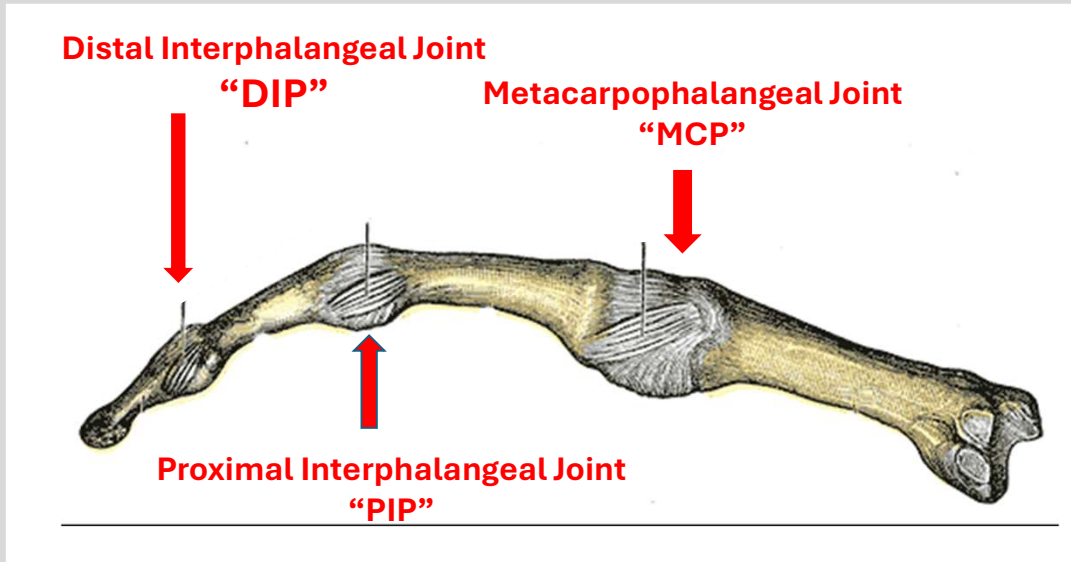


**THE OHIO STATE UNIVERSITY**  
WEXNER MEDICAL CENTER

## **Finger Dislocations**



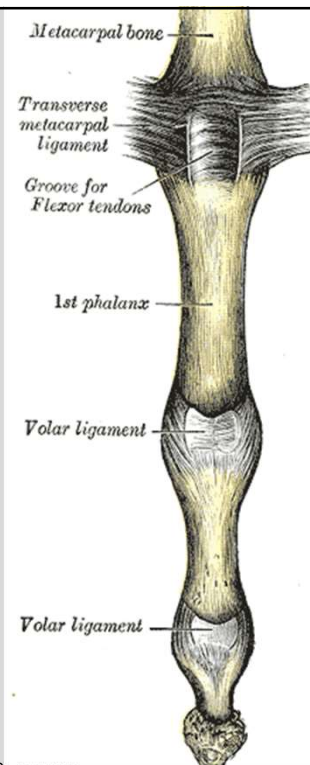
# Anatomy



Trade Secret, Confidential, Proprietary, Do Not Copy | OSU Wexner Medical Center © 2018

## Volar Plate

- Injury in dorsal dislocation



Trade Secret, Confidential, Proprietary, Do Not Copy | OSU Wexner Medical Center © 2018

## Epidemiology

Most Common Age Group:

- Adolescents & Young Adults
- Young athletes

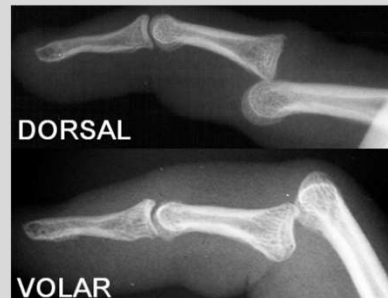**PIP Joint** is most commonly dislocated

Dorsal Dislocation is most common

\*Middle finger

Relatively Rare Dislocations

- Volar (Anterior) Dislocations
- MCP Dislocations



Trade Secret, Confidential, Proprietary, Do Not Copy | OSU Wexner Medical Center © 2018

## Types

1. Dorsal Dislocation

- Distal aspect of the dislocated finger displaced **posterior/dorsal**

2. Volar Dislocation

- Distal aspect of the dislocated finger displaced **anterior/ventral**
- Rare
- Typically, will require surgical correction

3. Lateral Dislocation

- Dislocated aspect displaced to the side

Trade Secret, Confidential, Proprietary, Do Not Copy | OSU Wexner Medical Center © 2018



## Reduction Technique

### Basic Concept of Dislocations:

- Initially recreate injury mechanism, then apply corrective force

#### Key Concept with Finger Dislocation

**Push > Pull**

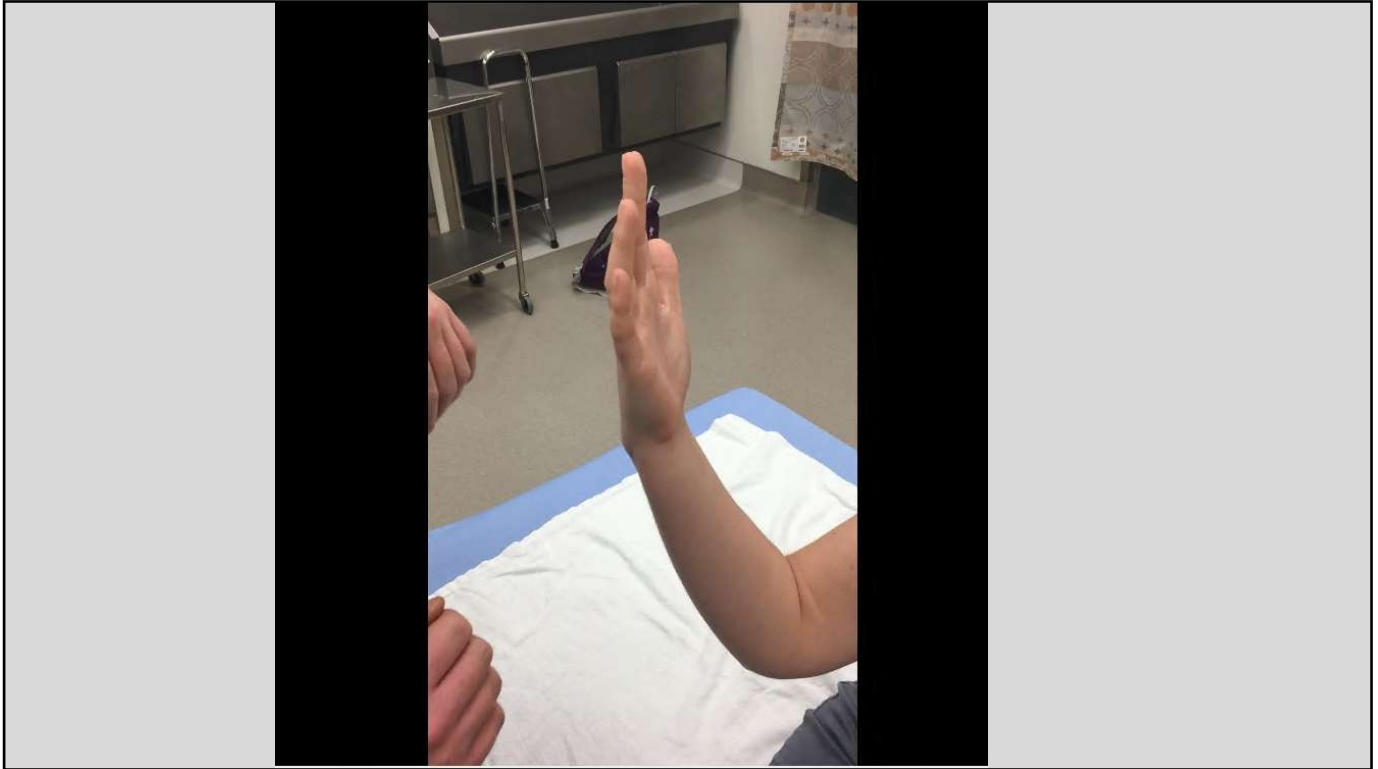
Trade Secret, Confidential, Proprietary, Do Not Copy | OSU Wexner Medical Center © 2018

## Technique

- Document neurovascular status
- Place your thumb behind dislocated joint
- Apply gentle steady in-line traction (**Pull**) on finger
- Gently **Push** forward with thumb while holding steady inline traction on dislocated finger
- Increase force slowly as needed until successful reduction
  - Dorsal: add hyper-extension
  - Ventral: add hyper-flexion

**Push > Pull**

Trade Secret, Confidential, Proprietary, Do Not Copy | OSU Wexner Medical Center © 2018



### Difficult Reductions

- Trick of the Trade
- Applying additional Hyperextension (dorsal dislocation) or Hyperflexion (volar dislocations) can help with difficult reductions



Video Reproduced  
with permission of  
Dr. Matthew  
Gammons

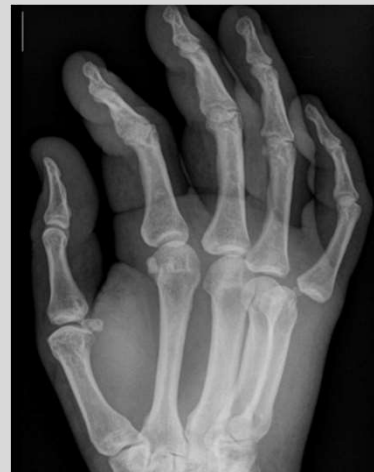## Post reduction

- Must assess and document tendon integrity
- **DIP dorsal:** dorsal splint in 10 – 20 degrees of flexion
- **DIP volar:** dorsal splint in extension
- **PIP dorsal:** dorsal splint with 20- 30 degrees of flexion
- **PIP volar:** dorsal splint in extension

1 | Trade Secret, Confidential, Proprietary, Do Not Copy | OSU Wexner Medical Center © 2018

## MCP Dislocations

- Dislocation of the joint at the base of the finger
- Not just a segment of the finger
- Rare Occurrence
  - Almost always dorsal dislocation
- Complex injury
  - Larger likelihood for soft tissue injury
  - Entrapment of volar plate

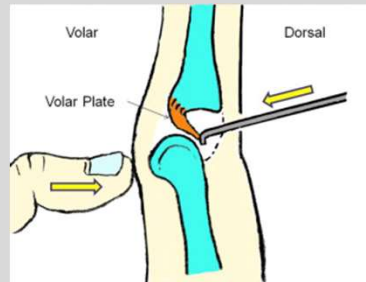
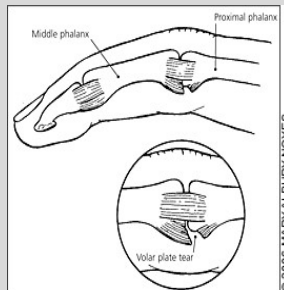


2 | Trade Secret, Confidential, Proprietary, Do Not Copy | OSU Wexner Medical Center © 2018

## Pitfalls

- **MCP Dislocations**

- **Key Concept:** Do not apply in-line traction (pull) on finger
  - **Why?:** Increases chances of volar plate being entrapped within the joint
  - Prevents adequate reduction and typically requires surgical intervention to restore full mobility of the joint



Images  
Reproduced  
with  
permission of  
Dr. Matthew  
Gammons

3 | Trade Secret, Confidential, Proprietary, Do Not Copy | OSU Wexner Medical Center © 2018

## MCP Reduction Technique

- **Dorsal MCP Joint Dislocation**
  - Apply anterior and superior pressure on proximal phalanx towards the palm & finger tip
  - Simultaneously put MCP joint into flexion while applying pressure to proximal phalanx (**Push**)
- **Trick of Trade**
  - **Flexing wrist may relax flexor tendons & aid with ease of reduction**
- **Post Reduction**
  - Place dorsal splint & maintain MCP joint flexed to 30 – 60 degrees
  - Prevent terminal extension

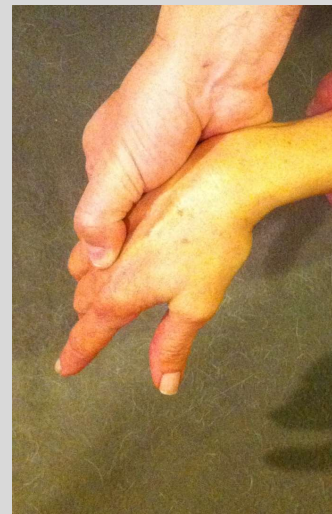


Image Reproduced with permission of Dr. Matthew Gammons

4 | Trade Secret, Confidential, Proprietary, Do Not Copy | OSU Wexner Medical Center © 2018

## Post-reduction Care

- Neurovascular Exam
  - Check sensation & capillary refill
- Splint or Buddy Tape
  - Depending on location of dislocation
  - Prevent re-dislocation. Stabilize unstable joint.
- Obtain X-ray within 24-48 hours following reduction